

Splenic implant preservation after conservation in lactated Ringer's solution

Preservação de implante esplênico autógeno após conservação em solução de Ringer-lactato

ARGOS SOARES DE MATOS FILHO, TCBC-MG¹; ANDY PETROIANU, ECBC-MG¹; VALBERT NASCIMENTO CARDOSO²; PAULA VIEIRA TEIXEIRA VIDIGAL³.

A B S T R A C T

Objective: to evaluate the morphology and function of autogenous splenic tissue implanted in the greater omentum, 24 hours after storage in Ringer-lactate solution. **Methods:** we divided 35 male rats into seven groups (n=5): Group 1: no splenectomy; Group 2: total splenectomy without implant; Group 3: total splenectomy and immediate autogenous implant; Group 4: total splenectomy, preservation of the spleen in Ringer-lactate at room temperature, then sliced and implanted; Group 5: total splenectomy, spleen sliced and preserved in Ringer-lactate at room temperature before implantation; Group 6: total splenectomy with preservation of the spleen in Ringer-lactate at 4°C and then sliced and implanted; Group 7: total splenectomy and the spleen sliced for preservation in Ringer-lactate at 4°C before implantation. After 90 days, we performed scintigraphic studies with Tc99m-colloidal tin (liver, lung, spleen or implant and clot), haematological exams (erythrogram, leucometry, platelets), biochemical dosages (protein electrophoresis) and anatomopathological studies. **Results:** regeneration of autogenous splenic implants occurred in the animals of the groups with preservation of the spleen at 4°C. The uptake of colloidal tin was higher in groups 1, 3, 6 and 7 compared with the others. There was no difference in hematimetric values in the seven groups. Protein electrophoresis showed a decrease in the gamma fraction in the group of splenectomized animals in relation to the operated groups. **Conclusion:** the splenic tissue preserved in Ringer-lactate solution at 4°C maintains its morphological structure and allows functional recovery after being implanted on the greater omentum.

Keywords: Spleen. Implants, Experimental. Trauma and Stressor Related Disorders. Organ Preservation.

INTRODUCTION

The damage control surgery consists of immediate interruption of bleeding and contamination due to severe trauma, followed by temporary closure of the body cavity and general stabilization of the patient. After 24 to 72 hours, a new operation is performed to repair the sustained damage¹⁻⁵. Total splenectomy has been used as a treatment for severe splenic lesions in this situation. Despite saving the patient's life, this procedure results in complications related to the asplenic state. To avoid this adversity, total removal of the spleen has been replaced by conservative treatments such as partial or subtotal splenectomy and autogenous implants⁶⁻¹⁰.

The spleen is responsible for 30% of the function of the mononuclear phagocytic system¹¹ and participates in the synthesis of complement factors,

immunoglobulins and other opsonins. It removes altered erythrocytes, anomalous particles and microorganisms from the circulation¹¹⁻¹³.

The first autogenous splenic implants are attributed to Griffini and Tizzioni (1883), who performed them in dogs. In men, in surgery to treat splenic trauma, it began to be used in 1896. Petroianu^{14,15}, from 1985, began to perform splenic autogenous implants in the greater omentum in patients with various affections, such as portal hypertension, myeloid hepatosplenomegaly, Gaucher's disease, leukemia, severe splenic pain and trauma¹⁵⁻¹⁸. The results of this procedure proved the effectiveness of the implants in preserving the functions of the spleen.

The aim of this study was to evaluate the morphological and functional preservation of the autogenous splenic tissue implanted on the day after

1 - Department of Surgery, Medical School, Federal University of Minas Gerais, (UFMG), Belo Horizonte, MG, Brazil. 2 - Department of Clinical and Toxicological Analysis (Radioisotope Laboratory), Faculty of Pharmacy (UFMG), Belo Horizonte, MG, Brazil. 3 - Department of Pathological Anatomy, Medical School (UFMG), Belo Horizonte, MG, Brazil.

removal of the spleen after its conservation in Ringer-lactate solution.

METHODS

This work was approved by the Ethics Committee on Animal Experimentation of the Federal University of Minas Gerais (UFMG), protocol 265/2008.

We randomly assigned 35 adult male rats (*Rattus norvegicus albinus*) of the Holtzman lineage to seven groups (n=5): Group 1- no splenectomy; Group 2- total splenectomy; Group 3- total splenectomy and implantation of autogenous splenic tissue in the greater omentum, immediately after spleen removal; Group 4- total splenectomy, preserving the entire spleen in Ringer-lactate solution at room temperature for 24 hours. The spleen was then sliced and implanted over the greater omentum; Group 5- total splenectomy and spleen slicing, with preservation in lactated Ringer's solution at room temperature for 24 hours, then implantation of the splenic slices in the greater omentum; Group 6- total splenectomy, preserving the whole spleen in Ringer-lactate solution at 4°C for 24 hours, then the spleen was sliced and implanted on the greater omentum; Group 7- total splenectomy and spleen slicing, with preservation in lactated Ringer's solution at 4°C for 24 hours, then implantation of the splenic slices in the greater omentum.

We grouped the rats into cages, one for each group. All received common chow for rats and water *ad libitum*. No procedure was performed in Group 1. In groups 2 to 7, after anesthesia with an association of ketamine hydrochloride (50mg/kg) and xylazine hydrochloride (5mg/kg) intramuscularly, total splenectomy was performed by means of a supraumbilical median laparotomy. In Group 3, the spleen was transversely sliced into five segments, three of which were sutured immediately over the greater omentum, with a continuous 6-0 prolene suture. At the end of this suture, the omentum was folded over to cover the splenic segments. After reviewing the abdominal cavity and hemostasis, the abdominal wall was closed in two planes using 2-0 silk monofilament sutures.

In animals from groups 4, 5, 6 and 7 the removed spleen, whole or sliced according to the group, was placed in a 25ml Becker flask containing Ringer-

lactate solution. After 24 hours, the abdominal cavity was reopened at the sutured site and the autogenous implants were performed using the same technique described for Group 3.

After the 90-day follow-up period, 1.0ml of 99mTc-labeled colloidal tin solution (110MBq/3mCi) was injected into the rats' tail vein after anesthesia. After 20 minutes, the whole rat was studied in a gamma camera. After a median laparotomy, 3.0ml of blood were collected from the abdominal vena cava for hematological study. This blood was collected in an EDTA flask, for erythrogram, fractional leucometry and platelet dosage. Another blood sample was collected in a vial without anticoagulant, to evaluate albumin and gamma fraction, using the protein electrophoresis method.

The spleen or implants, the liver, the lungs and a blood clot were then removed. Each of these structures was placed in a 20ml plastic beaker and inserted into the collimator of the gamma camera to measure the uptake of the radiopharmaceutical into each tissue and its blood remnant. After the scintigraphic study, the implants were fixed in 10% buffered saline formaldehyde for later histological evaluation.

The analysis of the phagocytic function, through the colloidal tin uptake by the scintigraphic method, was estimated by the radioactive counts per gram of tissue. Each sample was weighed immediately upon its withdrawal. Taking into account the weight of liver, spleen or implant samples, lung and blood clot, the radioactivity of the sample was calculated by counting the per minute (cpm) of uptake per gram (g) of tissue¹⁹⁻²¹.

For the purpose of calculation, the sum of the radioactivities of liver, splenic, lung and blood clot samples from the same animal was considered as equivalent to 100% of the radioactivity injected into it. To calculate the percentage of uptake of each tissue, we used the following formula²¹: % = (cpm/g da the sample x 100) / cpm/g of all samples.

Data were presented as mean and standard error of the mean. We used the Kolmogorov-Smirnov normality test, followed by the Bartlett test, to compare hematimetric and immune values and the percentage collected by the mononuclear phagocytic system of the liver, spleen or implants, lungs and clot of the different

groups. When the data displayed a normal distribution and same variance, we performed the parametric analysis of variance (ANOVA), followed by the Tukey-Kramer multiple comparison test. When the values did not present a normal distribution, we performed the Kruskal-Wallis test, followed by the Dunn-Bonferroni multiple comparison test. We considered the results significant for a probability of significance higher than 95% ($p < 0.05$).

RESULTS

All rats tolerated anesthesia well and evolved satisfactorily, with rapid postanesthetic recovery and apparently normal motor activity. Splenectomy was performed without intraoperative complications in all animals. All rats survived 90 days. In the reoperations after 90 days, we observed no intra-abdominal collections. In all animals of groups 4 and 5 we observed no splenic implants in the omentum. In groups 6 and 7 we found splenic implants with normal appearance (Figure 1).

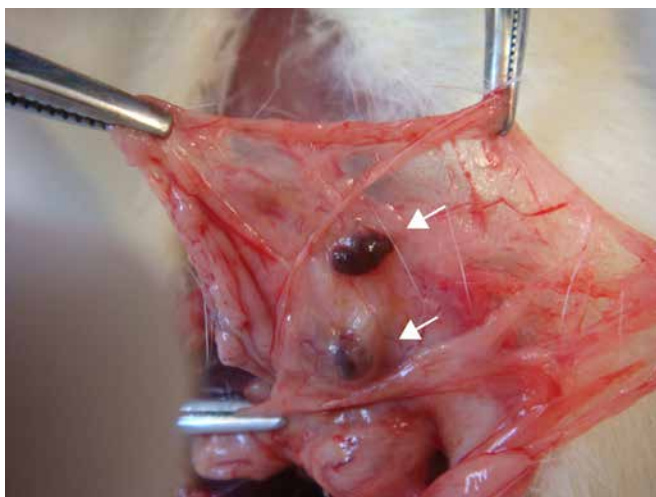


Figure 1. Macroscopic appearance of the implants (arrows) on the greater omentum

In the group in which total splenectomy was complemented with autogenous splenic implant in the greater omentum immediately after spleen removal (Group 3), scintigraphy showed clear images of the liver and splenic implants. However, there was no image of splenic implants in groups with preservation of spleen in Ringer-lactate solution at room temperature (Groups 4 and 5).

In the group with preservation of the whole spleen in Ringer-lactate solution at 4°C for 24 hours (Group 6) and in the group with preservation of the sliced spleen in Ringer-lactate solution at 4°C for 24 hours (Group 7), the scintigraphy showed clear images of the implants (Figures 2A and 2B). The omentum with the implants were removed for scintigraphic imaging due to the overlap of the liver.

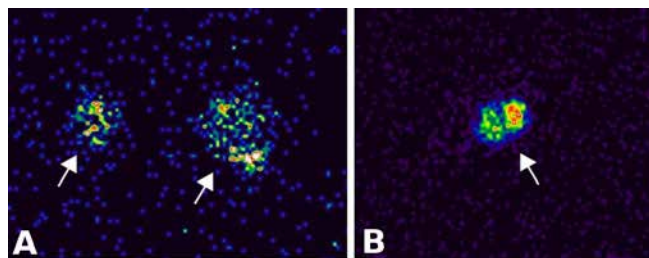


Figure 2. Scintigraphic image of the implants.

The relative uptake (percentage) of the radiopharmaceutical was greater in the splenic tissue of Group 1 (without splenectomy), Group 3 (immediate autogenous implant), Groups 6 and 7 (autogenous implants after preservation of the spleen in Ringer-lactate solution at 4°C) ($p = 0.0003$). In the other groups (2, 4 and 5) there was no record of splenic tissue (Figure 3).

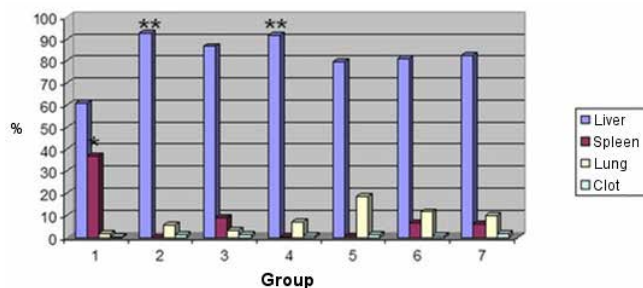


Figure 3. Uptake according to organ or tissue
 * $p = 0.0003$ (Kruskal-Wallis) – 1>2=4=5 (Dunn-Bonferroni); ** $p = 0.0271$ (ANOVA) – 2=4>1 (Tukey-Kramer).

Scintigraphic comparison of the tissues of the phagocytic mononuclear system indicated increased liver uptake in all groups, followed by the spleen (in the group where it was preserved) and then lung ($p = 0.0271$) (Figure 3). When comparing the presence of the radiopharmaceutical in the circulating blood (clot), there was no difference between groups ($p = 0.3155$).

Table 1 shows the comparison of erythrogram, hemoglobin and hematocrit levels between groups after 90 days. The mean leukocyte count increased in the group of animals with autogenous implantation of splenic fragments preserved at room temperature in relation to all other groups after 90 days of operation ($p=0.0235$).

Table 1. Results of the laboratory tests by group.

Study Group	Red blood cells ($\times 10^6/\text{dl}$)	Hemoglobin (g/dl)	Hematocrit (%)	Leukocytes ($\times 10^3/\text{dl}$)	Platelets ($\times 10^3/\text{dl}$)	Albumin protein electrophoresis (g/dl)	Protein electrophoresis Gamma Fraction (g/dl)
1	9.07 \pm 0.17	15.54	49.56 \pm 0.97	5.21 \pm 1.40	555.20 \pm 35.07	2.22 \pm 0.06	0.31 \pm 0.13
2	9.76 \pm 0.38	15.86 \pm 0.67	51.18 \pm 2.18	6.90 \pm 0.98	583.20 \pm 98.76	1.96 \pm 0.09	0.09 \pm 0.01
3	9.49 \pm 0.14	15.90 \pm 0.27	49.55 \pm 0.88	6.46 \pm 0.70	744.75 \pm 55.45	2.00 \pm 0.14	0.43 \pm 0.13
4	9.47 \pm 0.18	15.38 \pm 0.18	47.90 \pm 0.87	7.91 \pm 1.46	700.20 \pm 78.98	2.00 \pm 0.09	0.49 \pm 0.16
5	9.16 \pm 0.31	14.53 \pm 0.96	45.05 \pm 3.08	15.89 \pm 4.48	756.00 \pm 129.40	1.74 \pm 0.24	0.59 \pm 0.15
6	8.86 \pm 0.19	14.86 \pm 0.24	46.14 \pm 1.00	10.09 \pm 2.19	625.00 \pm 46.26	2.12 \pm 0.09	0.55 \pm 0.18
7	8.42 \pm 0.56	13.86 \pm 1.09	42.76 \pm 3.46	13.63 \pm 2.94	615.80 \pm 7.27	1.88 \pm 0.21	0.60 \pm 0.17

1- No splenectomy; 2- Splenectomy; 3- Total splenectomy with autogenous implant in the same operative procedure; 4- Total splenectomy with preservation of whole spleen in Ringer-lactate solution at room temperature and autogenous implant after 24 hours; 5- Total splenectomy with preservation of the sliced spleen in Ringer-lactate solution at room temperature and autogenous implant after 24 hours; 6- Total splenectomy with preservation of whole spleen in Ringer-lactate solution at 4°C and autogenous implant after 24 hours; 7- Total splenectomy with preservation of the sliced spleen in Ringer-lactate solution at 4°C and autogenous implant after 24 hours.

Autogenous implants of groups 3, 6 and 7 presented the same histological pattern (Figure 4), all without difference from the normal spleen aspect (Group 1).

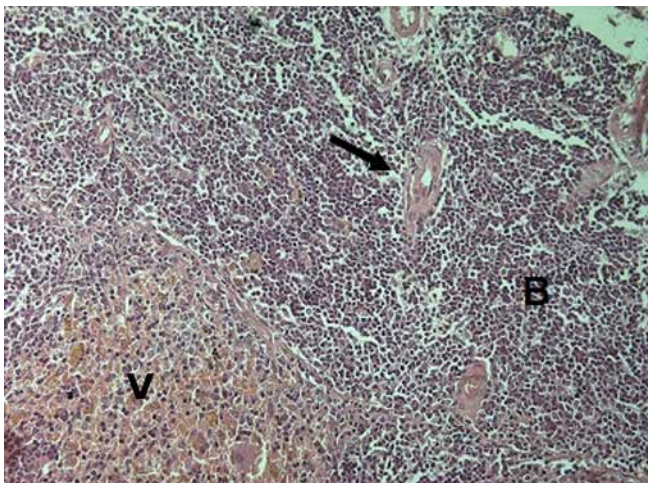


Figure 4. Histological appearance of implants. White pulp (B), red pulp (V) and central artery (arrow).

DISCUSSION

The spleen has several functions essential to the organism. In this organ, lymphocytes and monocytes are formed and phagocytosis of foreign particles, parasites, bacteria, fungi and viruses^{11,13} is responsible for 30% of the function of the mononuclear phagocytic system. The spleen also participates in the synthesis of complement factors and immunoglobulins. It differs from lymph nodes by receiving antigens from blood rather than from lymph. In addition to being essential to the body's defense system, the spleen removes altered erythrocytes and anomalous particles from the interior of circulating cells, such as the Howell-Jolly, Heintz and Pappenheimer corpuscles. This clearance is performed by splenic cord macrophages through direct phagocytosis, without the need for opsonization¹²⁻¹⁴.

Splenic lesions resulting from abdominal trauma are treated in most cases without operation due to the recognition of the importance of its immune function and

the adverse effects resulting from asplenia. Even when surgical intervention is necessary, the options have been preservation of the organ, with splenic sutures, vascular ligations, application of topical hemostatic agents, partial splenectomies and subtotal splenectomies. In cases where complete removal of the spleen is unavoidable, the autogenous splenic tissue implant is the alternative¹⁴⁻²².

The conduct of the splenic trauma should consider the patient as a whole, in its physiological and comorbid aspects. Decisions are differentiated in adults and children. In pediatric trauma, it is recommended at level 2B that the spleen should be preserved even partially, and non-operative treatment should be attempted even in patients with associated traumatic spinal cord or brain injury. In adults, splenectomy is indicated in the non-operative treatment failure, and this is still practiced in 24% to 35% of the patients, where only 1% to 6% of patients are submitted to splenorraphy. In this group, when traumatic brain injury or associated spinal cord injury is present, splenectomy is indicated²³.

Splenic autoimplantation was described mainly after splenectomy due to severe trauma¹⁴. This operation is based on splenosis, that is, the spontaneous implantation of spleen fragments in any part of the body, mainly in the abdomen, after severe splenic injury. The splenic tissue is able to maintain its vitality anywhere in the body in which it is implanted. Experimental studies have indicated that the best place to implant splenic fragments is the greater omentum. This choice is due not only to the rich omentum blood supply, but to the fact that its blood drains into the liver through the portal system, which is also the natural spleen drainage. This may be particularly useful in terms of splenic functions and production of immunoglobulins, complements and metabolic substances²⁴⁻²⁹.

The literature shows some complications of splenic implants, such as hemorrhage, intestinal obstruction or perforation. These complications occur

when the implants are of larger size or are not covered by the greater omentum to avoid adhesions with the intestine or other abdominal structure.

Pister & Leon Pachter³⁰ reviewed splenic implants in humans and animals but failed to demonstrate a reduction in morbidity and mortality rates related to subsequent bacterial infections. Other studies have shown that there is a need for at least 25% of the amount of tissue in a normal spleen to preserve all its functions^{25,29-32}. The experience of the present research group with splenic implants for portal hypertension, Gaucher's disease, and myeloid metaplasia, as well as in the presence of chronic lymphocytic leukemia, have shown absence of abnormal particles in blood samples, suggesting that phagocytosis function is present in the implanted splenic tissue¹⁴⁻¹⁸.

The Ringer-lactate solution is a low-cost physiological solution available in most surgical wards. This study showed that this solution was sufficient to preserve the vitality of the splenic tissue at low temperatures. Still remains the doubt about the best temperature to preserve the splenic tissue, although the temperature of 4°C in a common refrigerator is adequate to maintain its vitality. In animals in which the implant was performed after preservation in Ringer-lactate at 4°C (groups 6 and 7), the scintigraphic examination was not different from those with implants performed immediately after spleen removal (Group 2). This confirms the good clearance function present on the day after spleen removal.

According to the indications of this experimental study, it is pertinent to suppose that in cases of severe trauma with indication of total splenectomy, the removed spleen can be preserved in refrigerated Ringer-lactate solution to maintain its vitality, and be used as an autogenous implant, in the greater omentum, during the reoperation to repair the damage. This procedure, which lasts less than five minutes, can restore splenic functions and prevent asplenia complications.

R E S U M O

Objetivo: avaliar morfologia e função de tecido esplênico autógeno, implantado no omento maior, 24 horas após conservação em solução de Ringer-lactato. **Métodos:** foram estudados 35 ratos machos, distribuídos em sete grupos (n=5): Grupo 1: sem esplenectomia; Grupo 2: esplenectomia total sem implante; Grupo 3: esplenectomia total e implante autógeno imediato; Grupo 4: esplenectomia total, preservação do baço em Ringer-lactato à temperatura ambiente, em seguida, fatiado e implantado; Grupo 5: esplenectomia total, baço fatiado e preservado em Ringer-lactato à temperatura ambiente antes de ser implantado; Grupo 6: esplenectomia total com preservação do baço em Ringer-lactato a 4°C e, em seguida, fatiado e implantado; Grupo 7: esplenectomia total e baço fatiado, para preservação em Ringer-lactato a 4°C antes de ser implantado. Após 90 dias, realizaram-se estudos cintilográficos com estanho coloidal-Tc99m (fígado, pulmão, baço ou implante e coágulo), hematológicos (eritograma, leucometria, plaquetas), bioquímicos (eletroforese de proteínas) e anatomopatológicos. **Resultados:** ocorreu regeneração dos implantes esplênicos autógenos nos animais dos grupos com preservação do baço a 4°C. A captação de estanho coloidal foi superior nos grupos 1, 3, 6 e 7 em relação aos demais. Não houve diferença nos valores hematimétricos nos sete grupos. A eletroforese de proteínas mostrou diminuição da fração gama no grupo de animais esplenectomizados em relação aos grupos operados. **Conclusão:** o tecido esplênico conservado em solução de Ringer-lactato à temperatura de 4°C mantém sua estrutura morfológica e permite a recuperação funcional após ser implantado sobre o omento maior.

Descritores: Baço. Implantes Experimentais. Redução do Dano. Preservação de Órgãos.

REFERENCES

1. Waibel BH, Rotondo MM. Damage control surgery: it's evolution over the last 20 years. *Rev Col Bras Cir.* 2012;39(4):314-21.
2. Chovanes J, Cannon JW, Nunez TC. The evolution of damage control surgery. *Surg Clin North Am.* 2012; 92(4):859-75.
3. Normando GR JR. [Damage control surgery and Latin America's contributions to it]. *Rev Col Bras Cir.* 2011;38(1):1-2. Portuguese.
4. Duchesne JC, McSwain NE Jr, Cotton BA, Hunt JP, Dellavolpe J, Lafaro K, et al. Damage control resuscitation: the new face of damage control. *J Trauma.* 2010;69(4):976-90.
5. Edelmuth RCI, Buscariolli YS, Ribeiro MA Jr. Cirurgia para controle de danos: estado atual. *Rev Col Bras Cir.* 2013;40:142-151.
6. Beuran M, Gheju I, Venter MD, Marian RC, Smarandache R. Non-operative management of splenic trauma. *J Med Life.* 2012;5(1):47-58.
7. Liu PP, Liu HT, Hsieh TM, Huang CY, Ko SF. Nonsurgical management of delayed splenic rupture after blunt trauma. *J Trauma Acute Care Surg.* 2012;72(4):1019-23.
8. Skattum J, Naess PA, Gaarder C. Non-operative management and immune function after splenic injury. *Br J Surg.* 2012; 99 Suppl 1:59-65.
9. Demetriades D, Scalea TM, Degiannis E, Barmparas G, Konstantinidis A, Massahis J, et al. Blunt splenic trauma: splenectomy increases early infectious complications: a prospective multicenter study. *J Trauma Acute Care Surg.* 2012;72(1):229-34.
10. Renzulli P, Gross T, Schnüriger B, Schoepfer AM, Inderbitzin D, Exadaktylos AK, et al. Management of blunt injuries to the spleen. *Br J Surg.* 2010;97(11):1696-703.
11. Llende M, Santiago-Delpin EA, Lavergne J. Immunobiological consequences of splenectomy: a review. *J Surg Res.* 1986;40(1):85-94.
12. Müftüoğlu TM1, Köksal N, Ozkutlu D. Evaluation of phagocytic function of macrophages in rats after partial splenectomy. *J Am Coll Surg.* 2000;191(6):668-71.
13. Lynch AM, Kapila R. Overwhelming postsplenectomy infection. *Infect Dis North Am.* 1986;10(4):693-707.
14. Petroianu A, Simal CJR, Barbosa AJA. Assessment of phagocytic function in remnants of subtotal splenectomy and in autologous spleen implantation. *Med Sci Res.* 1993;21:715-7.
15. Resende V, Petroianu A, Junior WCT. Autotransplantation for treatment of severe splenic lesions. *Emerg Radiol.* 2002;9(4):208-12.
16. Resende V, Petroianu A. Funções do remanescente esplênico após esplenectomia subtotal ou auto-implantes esplênicos para tratamento de lesões graves do baço humano. *Rev Med Minas Gerais.* 2001;11(1):59.
17. Marques RG, Petroianu A, Coelho JM, Portela MC. Regeneration of splenic autotransplants. *Ann Hematol.* 2002;81(11):622-6.

18. Petroianu A, Petroianu LP. Splenic autotransplantation for treatment of portal hypertension. *Can J Surg*. 2005;48(5):382-6.
19. Petroianu A, Simal CJRS. Shifts in the reticuloendothelial system uptake pattern induced by carbon colloid in the rat. *Med Sci Res*. 1993;21:311-2.
20. Marques RG, Petroianu A, de Oliveira MB, Bernardo-Filho M, Boasquevisque EM, Portela MC. Bacterial clearance after total splenectomy and splenic autotransplantation in rats. *Appl Radiat Isot*. 2002;57(6):767-71.
21. Marques RG, Petroianu A, Coelho JMCO, Portela MC. Morfologia e função fagocitária de implante esplênico autógeno regenerado em ratos. *Acta Cir Bras*. 2004;19(6):642-8.
22. Silva RG, Petroianu A, Silva MG, Diniz SOF, Cardoso VN. Influência das operações sobre o baço na distribuição da *Escherichia coli* no sistema mononuclear fagocitário. *Rev Col Bras Cir*. 2003;30(1):65-71.
23. Coccolini F, Montori G, Catena F, Kluger Y, Biffl W, Moore EE, et al. Splenic trauma: WSES classification and guidelines for adult and pediatric patients. *World J Emerg Surg*. 2017;12:40.
24. Livingston CD, Levine BA, Sirinek KR. Site of splenic autotransplantation effects protection from sepsis. *Am J Surg*. 1983;146(6):734-7.
25. Alvarez FE, Greco RS. Regeneration of the spleen after ectopic implantation and partial splenectomy. *Arch Surg*. 1980;115(6):772-5.
26. Cooney DR, Dearth JC, Swanson SE, Dewanjee MK, Telander RL. Relative merits of partial splenectomy, splenic reimplantation, and immunization in preventing postsplenectomy infection. *Surgery*. 1979;86(4):561-9.
27. Clayer M, Drew P, Leong A, Jamieson GG. The vascular supply of splenic autotransplants. *J Surg Res*. 1992;53(5):475-84.
28. Iinuma H, Okinaga K, Sato S, Tomioka M, Matsumoto K. Optimal site and amount of splenic tissue for autotransplantation. *J Surg Res*. 1992;53(2):109-16.
29. Weber T1, Hanisch E, Baum RP, Seufert RM. Late results of heterotopic autotransplantation of splenic tissue into the greater omentum. *World J Surg*. 1998;22(8):883-9.
30. Pisters PW, Pachter HL. Autologous splenic transplantation for splenic trauma. *Ann Surg*. 1994;219(3):225-35.
31. Drew PA, Clayer MT, Jamieson GG. The value of splenic autotransplantation. *Arch Surg*. 1990;125(9):1224.
32. Witte CL, Witte MH. Enlargement of splenic implants. *Surgery*. 1995;117(3):357.

Received in: 03/08/2017

Accepted for publication: 17/09/2017

Conflict of interest: none.

Source of funding: none.

Mailing address:

Argos Soares de Matos Filho

E-mail: argosfilho@yahoo.com.br / argos.matos@gmail.com

